



(19) **United States**

(12) **Patent Application Publication**
TESFAYESUS et al.

(10) **Pub. No.: US 2017/0202482 A1**

(43) **Pub. Date: Jul. 20, 2017**

(54) **SCREENING DEVICES AND METHODS FOR OBSTRUCTIVE SLEEP APNEA THERAPY**

Publication Classification

(71) Applicant: **Cyberonics, Inc.**, Houston, TX (US)

- (51) **Int. Cl.**
- A61B 5/08* (2006.01)
- A61N 1/36* (2006.01)
- A61B 1/233* (2006.01)
- A61N 1/05* (2006.01)
- A61B 1/267* (2006.01)
- A61B 5/00* (2006.01)

(72) Inventors: **Wondimeneh TEFAYESUS**, St. Paul, MN (US); **Stephen L. BOLEA**, Watertown, MN (US); **Peter R. EASTWOOD**, Western Australia (AU); **David R. HILLMAN**, Western Australia (AU)

- (52) **U.S. Cl.**
- CPC *A61B 5/0826* (2013.01); *A61B 1/267* (2013.01); *A61B 5/4552* (2013.01); *A61B 1/233* (2013.01); *A61N 1/0551* (2013.01); *A61N 1/3601* (2013.01); *A61N 1/3611* (2013.01)

(73) Assignee: **Cyberonics, Inc.**, Houston, TX (US)

(21) Appl. No.: **15/418,467**

(22) Filed: **Jan. 27, 2017**

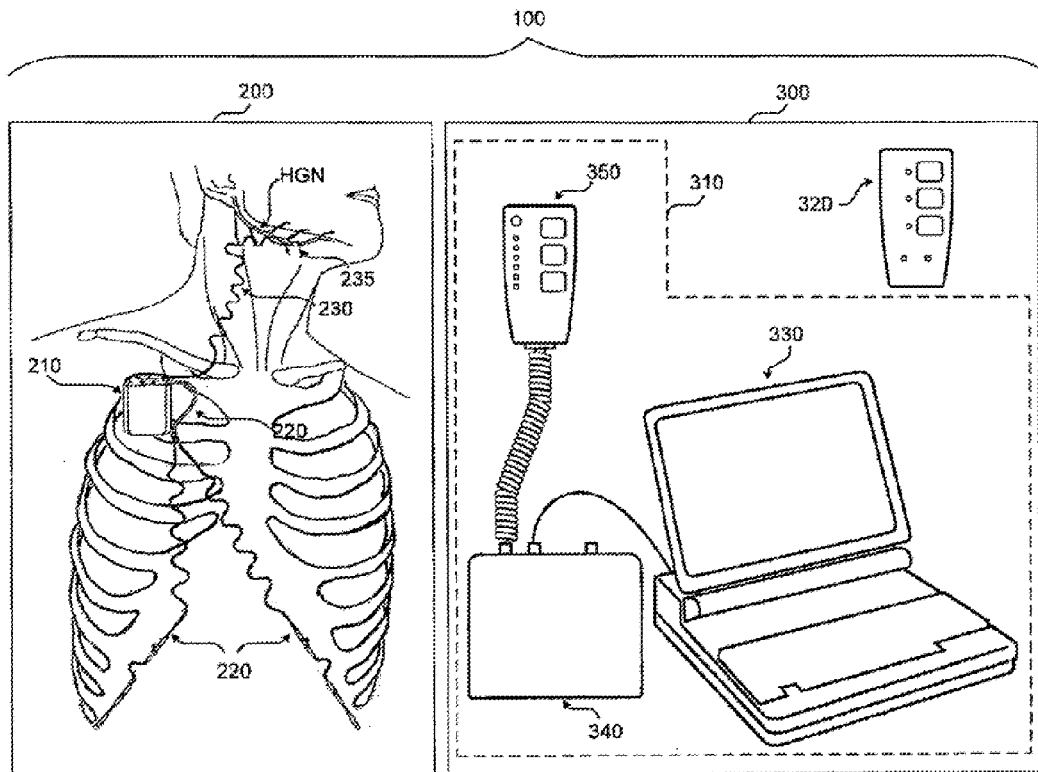
Related U.S. Application Data

(63) Continuation of application No. 14/803,779, filed on Jul. 20, 2015, now Pat. No. 9,555,247, which is a continuation of application No. 14/475,130, filed on Sep. 2, 2014, now Pat. No. 9,113,838, which is a continuation of application No. 13/205,315, filed on Aug. 8, 2011, now Pat. No. 8,855,771, which is a continuation of application No. 13/113,524, filed on May 23, 2011, now abandoned.

(60) Provisional application No. 61/437,573, filed on Jan. 28, 2011, provisional application No. 61/467,758, filed on Mar. 25, 2011.

(57) **ABSTRACT**

Devices and methods for treating obstructive sleep apnea by first performing an assessment of the patient that involves observing the patient's upper airway during a tongue protrusion maneuver. The assessment may, for example, be done using endoscopy to observe the upper airway while the patient is awake in the supine position. An adequate response of the upper airway during the tongue protrusion maneuver is indicative of likely therapeutic success with hypoglossal nerve stimulation, and may be used for making clinical decisions. The principles of the present invention may be applied to other therapeutic interventions for OSA involving the upper airway.



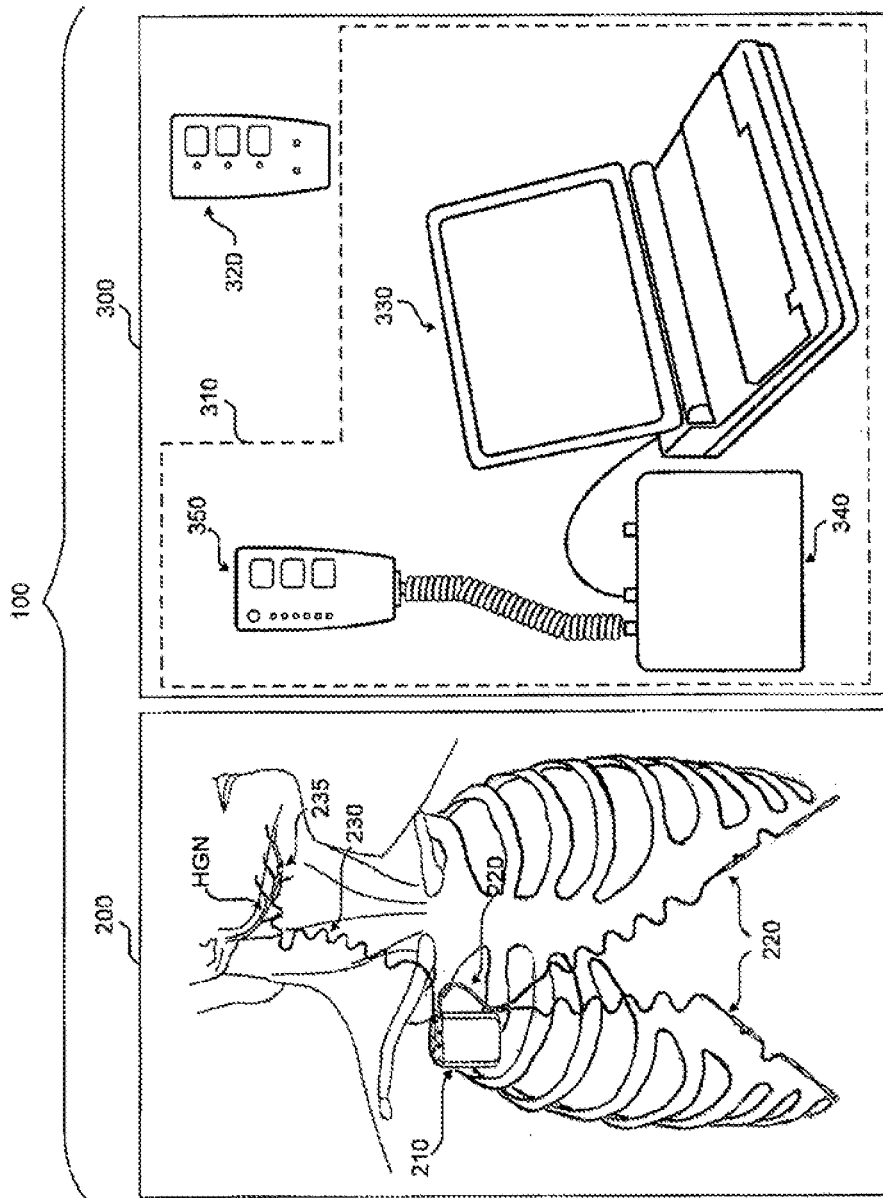


FIG. 1

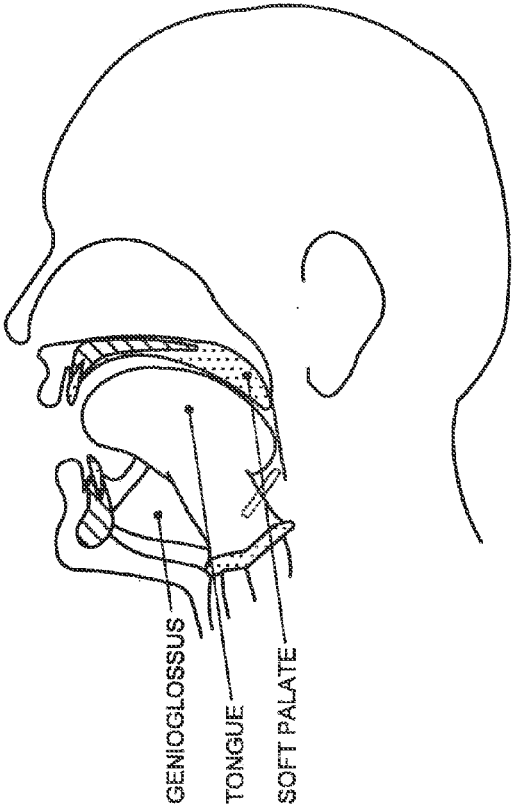


FIG. 2A

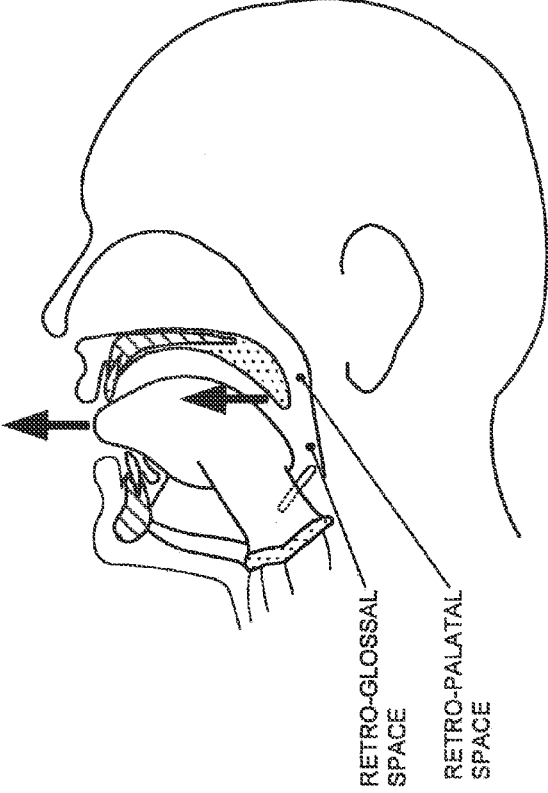
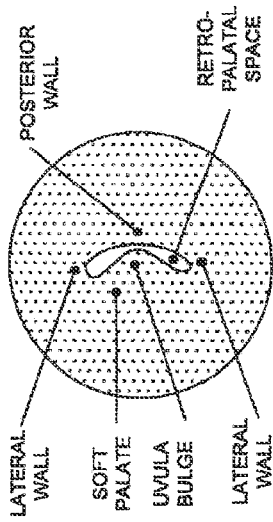
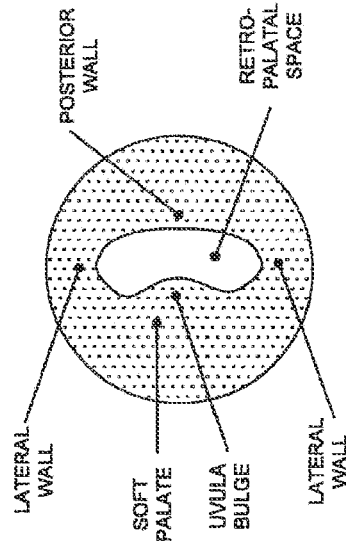


FIG. 2B



VIEW FROM RETRO-PALATAL LEVEL
(NO TONGUE PROTRUSION)

FIG. 3B



VIEW FROM RETRO-PALATAL LEVEL
(TONGUE PROTRUSION)

FIG. 3C

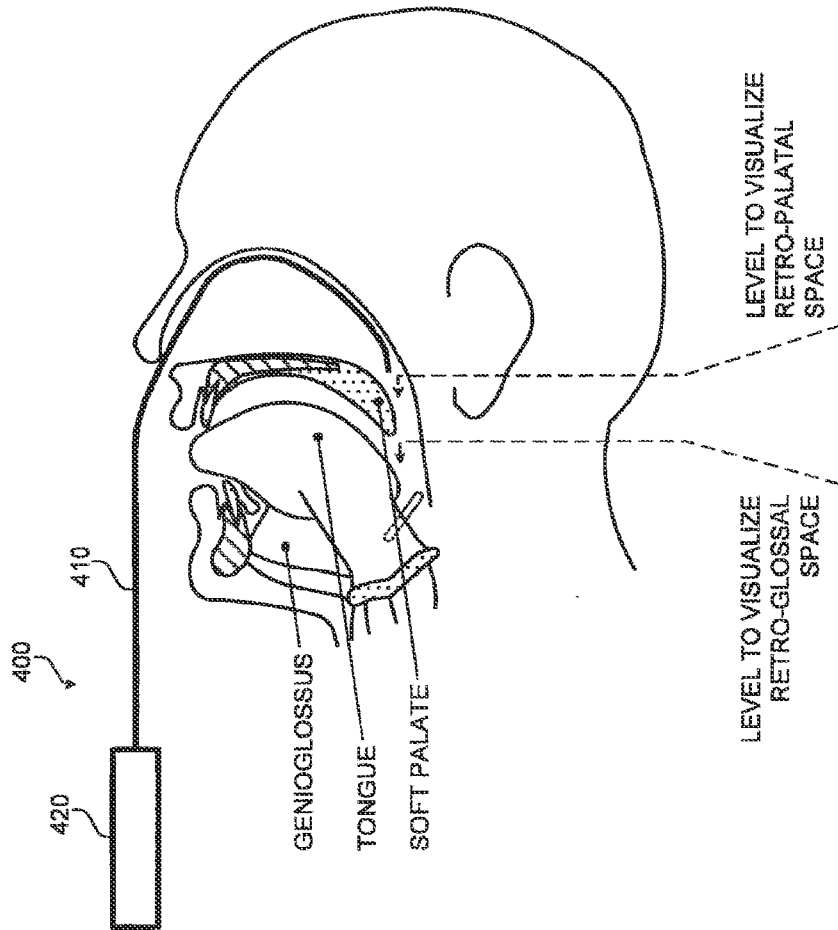


FIG. 3A

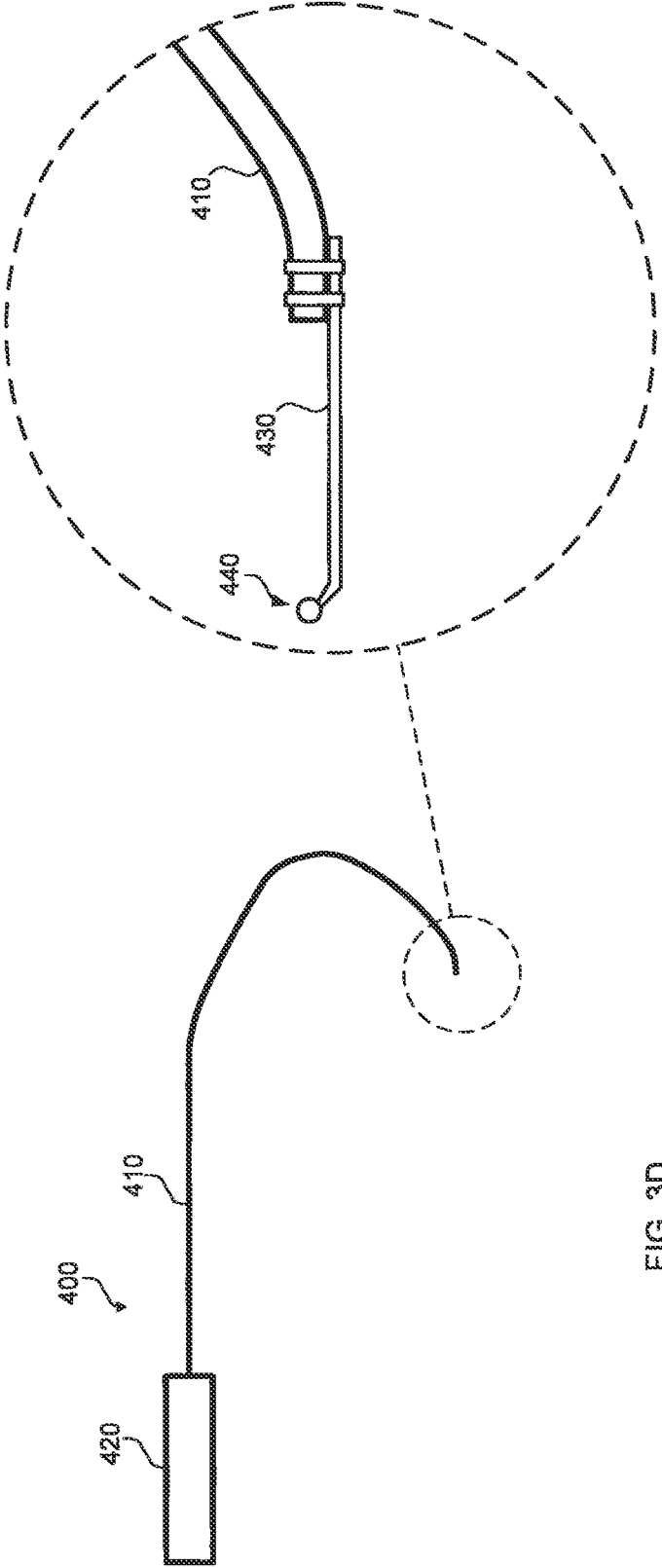


FIG. 3D

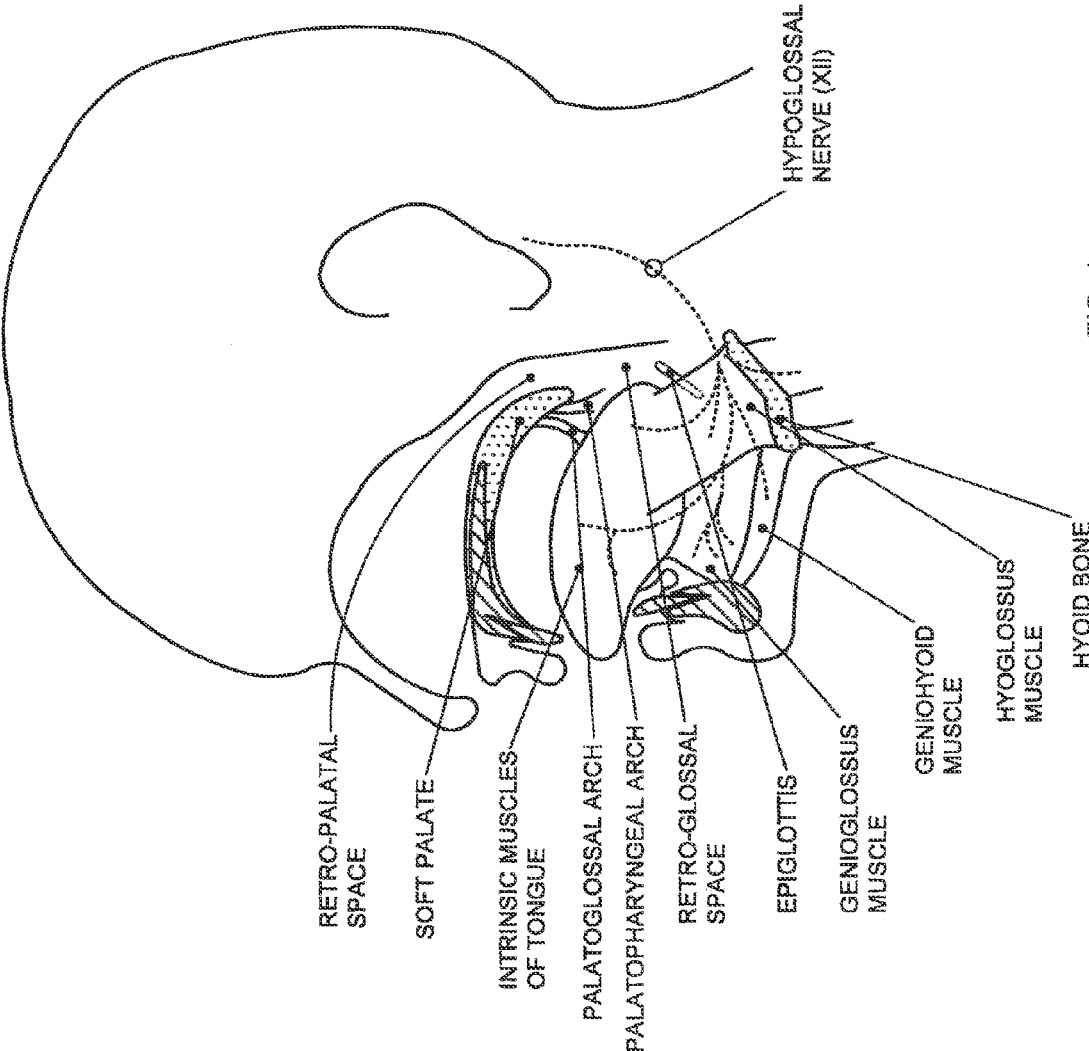


FIG. 4

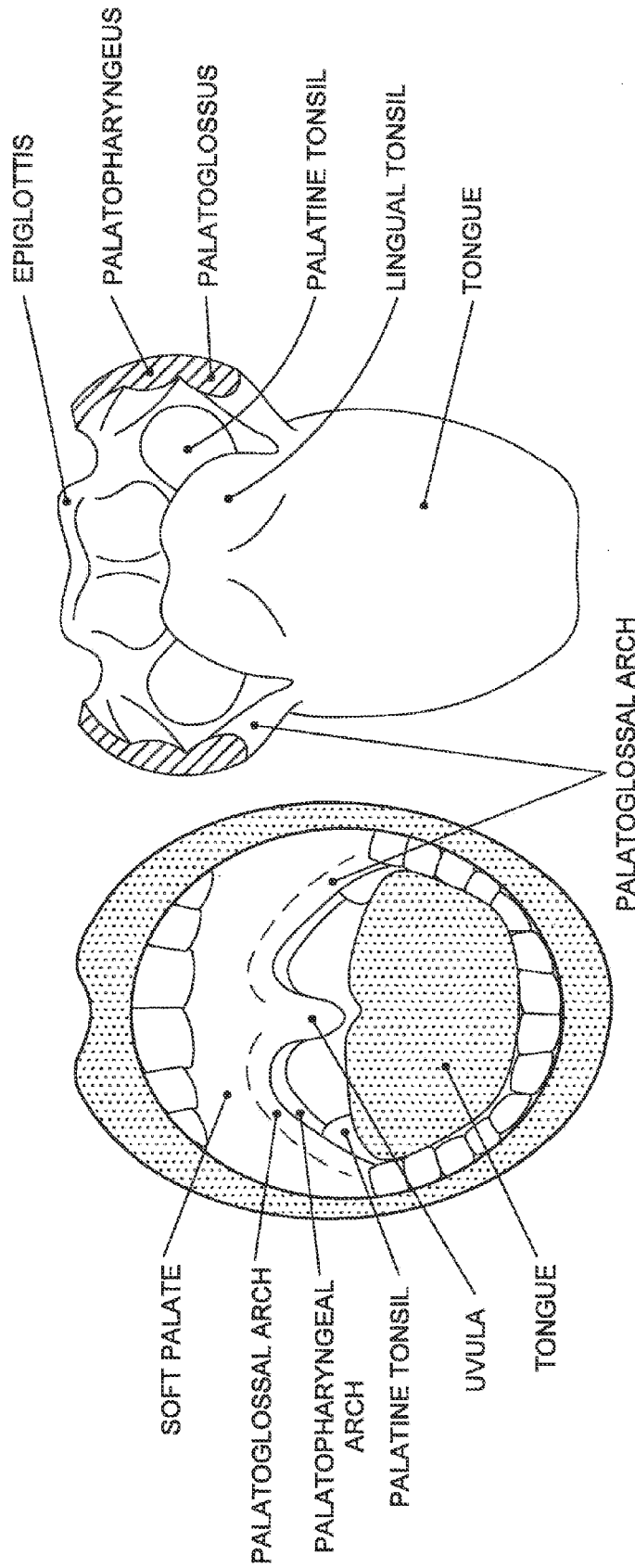


FIG. 6

FIG. 5

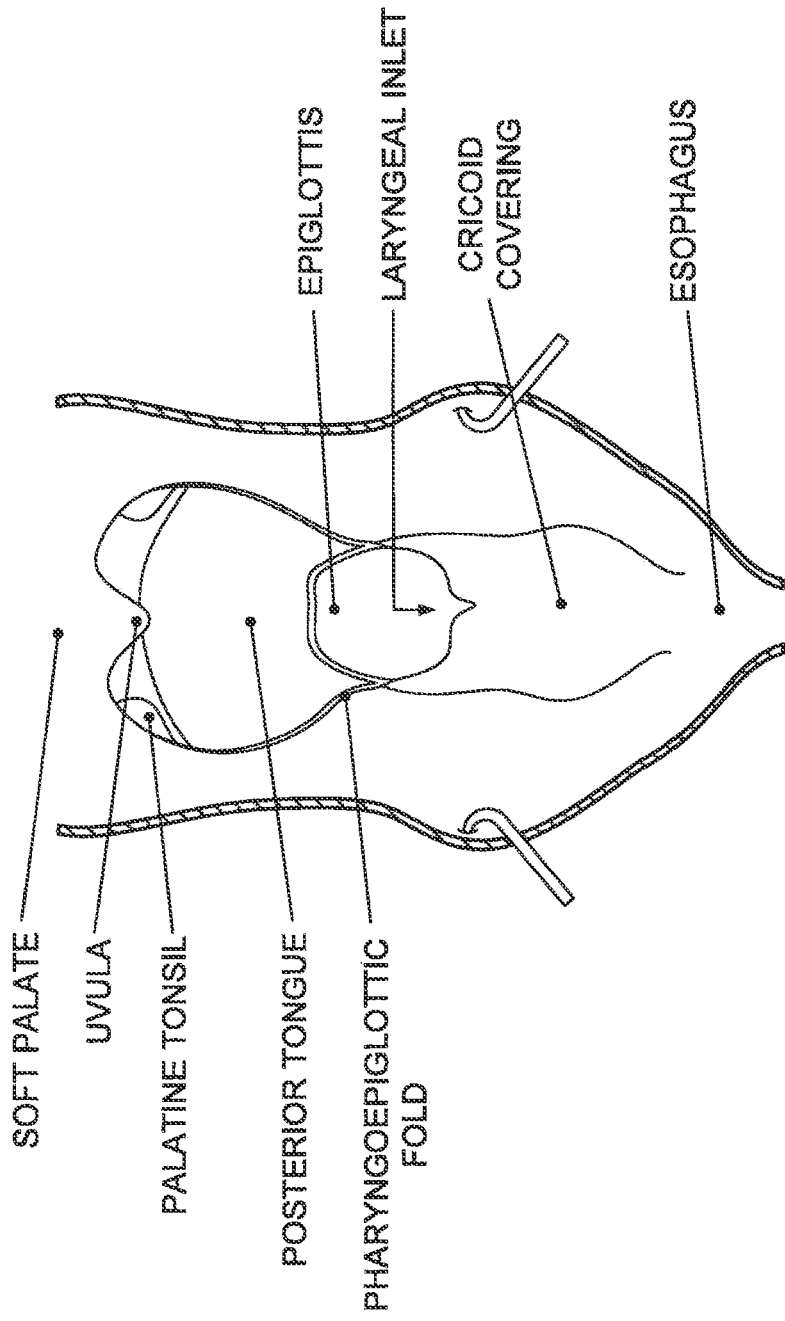


FIG. 7

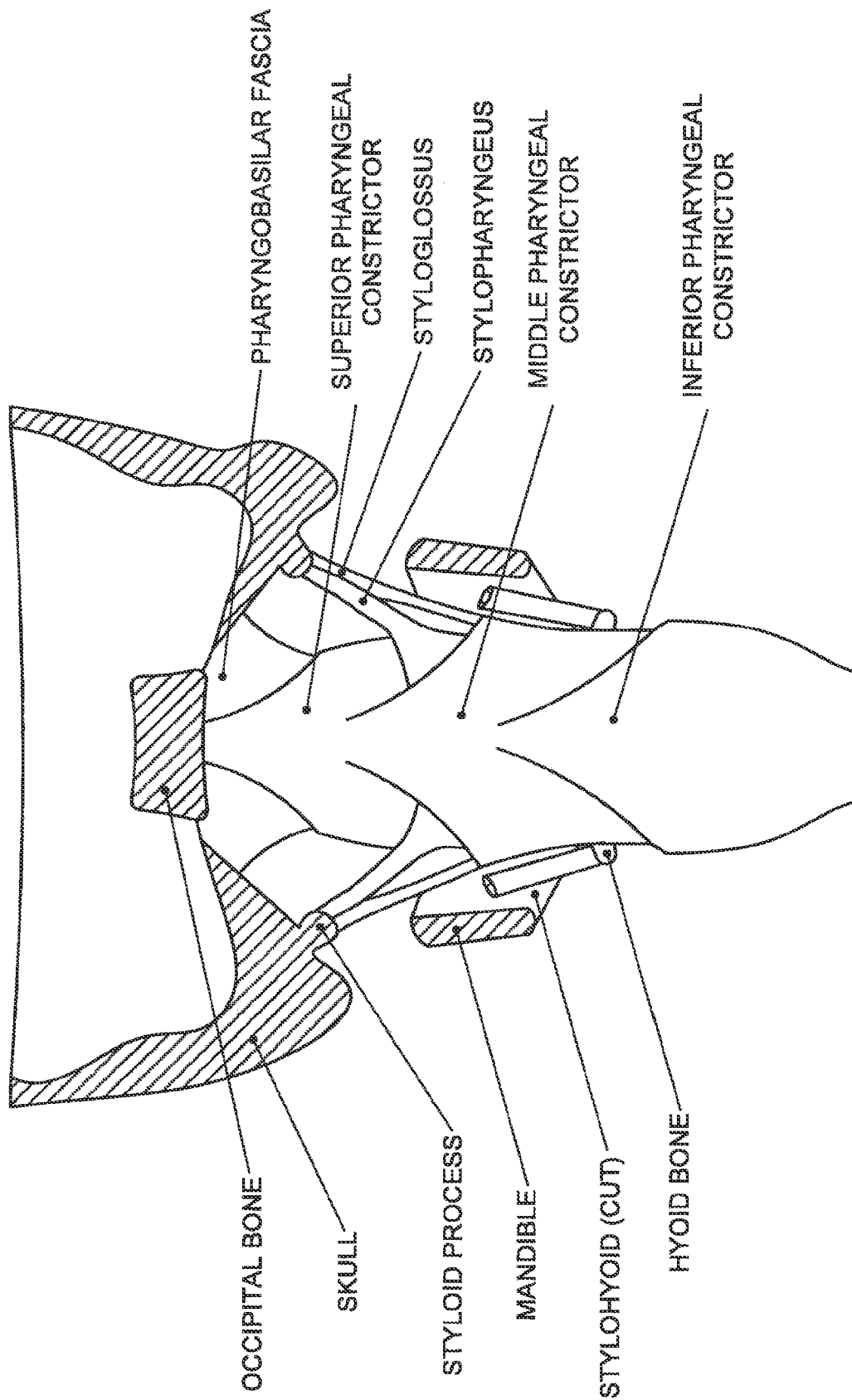


FIG. 8

SCREENING DEVICES AND METHODS FOR OBSTRUCTIVE SLEEP APNEA THERAPY

CROSS REFERENCE TO RELATED APPLICATIONS

[0001] This patent application is a continuation of U.S. patent application Ser. No. 14/803,779, filed Jul. 20, 2015, entitled SCREENING DEVICES AND METHODS FOR OBSTRUCTIVE SLEEP APNEA THERAPY, which is a continuation of U.S. patent application Ser. No. 14/475,130, filed Sep. 2, 2014, entitled SCREENING DEVICES AND METHODS FOR OBSTRUCTIVE SLEEP APNEA THERAPY, now U.S. Pat. No. 9,113,838 which is a continuation of U.S. patent application Ser. No. 13/205,315, filed Aug. 8, 2011, entitled SCREENING DEVICES AND METHODS FOR OBSTRUCTIVE SLEEP APNEA THERAPY, now U.S. Pat. No. 8,855,771, which is a continuation of U.S. patent application Ser. No. 13/113,524, filed May 23, 2011, now abandoned, which claims the benefits of priority under 35 U.S.C. §§119 and 120 to U.S. Provisional Patent Application No. 61/437,573, filed Jan. 28, 2011, entitled OBSTRUCTIVE SLEEP APNEA TREATMENT DEVICES, SYSTEMS AND METHODS, and U.S. Provisional Patent Application No. 61/467,758, filed Mar. 25, 2011, entitled SCREENING DEVICES AND METHODS FOR OBSTRUCTIVE SLEEP APNEA THERAPY. This patent application is related to U.S. patent application Ser. No. 13/106,460, filed May 12, 2011, entitled OBSTRUCTIVE SLEEP APNEA TREATMENT DEVICES, SYSTEMS AND METHODS to Bolea et al., which claims the benefit of U.S. Provisional Patent Application No. 61/437,573, filed Jan. 28, 2011, entitled OBSTRUCTIVE SLEEP APNEA TREATMENT DEVICES, SYSTEMS AND METHODS. This patent application is also related to U.S. patent application Ser. No. 13/251,856, filed Oct. 3, 2011, now U.S. Pat. No. 8,386,046, entitled SCREENING DEVICES AND METHODS FOR OBSTRUCTIVE SLEEP APNEA THERAPY, which is a continuation of U.S. patent application Ser. No. 13/205,315, filed Aug. 8, 2011, entitled SCREENING DEVICES AND METHODS FOR OBSTRUCTIVE SLEEP APNEA THERAPY, and to U.S. patent application Ser. No. 14/178,104, filed Feb. 11, 2014, entitled OBSTRUCTIVE SLEEP APNEA TREATMENT DEVICES, SYSTEMS AND METHODS, which is a continuation-in-part of U.S. patent application Ser. No. 13/205,315. The entire disclosures of all of the above-listed applications are incorporated by reference herein in their entireties.

FIELD

[0002] The inventions described herein relate to devices and methods for assessing and treating the upper airway. More particularly, the inventions described herein relate to devices and methods for assessing and treating the upper airway in patients with obstructive sleep apnea.

BACKGROUND

[0003] Hypoglossal nerve stimulation has been proposed for the treatment of obstructive sleep apnea. An example of an implantable hypoglossal nerve stimulation system is described in U.S. Pat. No. 7,809,442 to Bolea et al. Published data suggest that response to hypoglossal nerve stimulation varies across subjects. Before undergoing a

surgical procedure to implant a hypoglossal nerve stimulation system, it would be desirable to understand the likelihood of therapeutic success, and make clinical judgments accordingly.

SUMMARY

[0004] To address this and other unmet needs, the present invention offers, in one example embodiment, a method for treating obstructive sleep apnea by first performing an assessment of the patient that involves observing the patient's upper airway during a tongue protrusion maneuver. The assessment may, for example, be done using endoscopy to observe the upper airway while the patient is awake in the supine position. The tongue protrusion maneuver may, for example, involve the patient volitionally protruding the tongue to its maximal extent with the mouth open or the lips loosely touching the tongue. The tongue protrusion maneuver mimics the effect of genioglossus activation by hypoglossal nerve stimulation (HGNS). Thus, an adequate increase in airway size during the tongue protrusion maneuver would be indicative of likely therapeutic success with HGNS. If the assessment shows an adequate increase in airway size during the maneuver, a HGNS device may be implanted in the patient with a higher confidence in a successful outcome. The principles of the present invention may be applied to other therapeutic interventions for OSA involving the upper airway.

BRIEF DESCRIPTION OF THE DRAWINGS

[0005] It is to be understood that both the foregoing summary and the following detailed description are provided by way of example, not limitation. Together with the following detailed description, the drawings illustrate example embodiments and serve to explain certain principles of the invention. In the drawings,

[0006] FIG. 1 is a schematic illustration of a hypoglossal nerve stimulation system;

[0007] FIGS. 2A and 2B are schematic illustrations showing simplified structures of the upper airway in a lateral dissection with the palate and mandible shown in medial sagittal section;

[0008] FIG. 3A is a schematic illustration showing an endoscope inserted into the airway

[0009] FIGS. 3B and 3C are views of the upper airway from the endoscope shown in FIG. 3A while the tongue is in a resting awake state (FIG. 3B) and during a tongue protrusion maneuver (FIG. 3C);

[0010] FIG. 3D is a schematic illustration of a modified endoscope;

[0011] FIG. 4 is a schematic illustration showing the structures of the upper airway in a lateral dissection with the palate and mandible shown in medial sagittal section;

[0012] FIG. 5 is a schematic illustration showing the structures of the upper airway from the oral cavity;

[0013] FIG. 6 is a schematic illustration showing isolated structures of the upper airway in a transverse section;

[0014] FIG. 7 is a schematic illustration showing structures of the upper airway in a posterior dissection of the interior pharynx;

[0015] FIG. 8 is a schematic illustration showing structures of the upper airway in a posterior dissection of the exterior pharynx.

DETAILED DESCRIPTION

[0016] The following detailed description should be read with reference to the drawings in which similar elements in different drawings are numbered the same. The drawings, which are not necessarily to scale, depict illustrative embodiments and are not intended to limit the scope of the invention.

[0017] FIG. 1 schematically illustrates a hypoglossal nerve stimulation (HGNS) system **100** comprising internal components **200** and external components **300**. The HGNS system **100** is intended to treat obstructive sleep apnea (OSA) by increasing neuromuscular activity of the genioglossus muscle via stimulation of the hypoglossal nerve (HGN) synchronous with inspiration to mitigate upper airway collapse during sleep. Stimulation is generated by an implantable neurostimulator (INS) **210**, synchronized with inspiration as measured by the respiration sensing lead (RSL) **220** using bio-impedance, and delivered to the hypoglossal nerve by a stimulation lead (STL) **230**. A programmer system **310** and a therapy controller **320** are wirelessly linked to the INS **210**. The programmer system **310** includes a computer **330**, a programmer interface **340**, and a programmer head **350**. The programmer system **310** is used by the physician to control and program the INS **210** during surgery and therapy titration, and the therapy controller **320** is used by the patient to control limited aspects of therapy delivery (e.g., start, stop, and pause).

[0018] The implanted components **200** of the HGNS system **100** include the INS **210**, STL **230**, and RSL **220**. The INS is designed to accommodate one STL **230** and one RSL **220**. One STL **230** may be used for unilateral implantation and unilateral hypoglossal nerve stimulation. Similarly, one RSL **220** may be used for respiration detection, and may be bifurcated as shown.

[0019] The implanted components **200** may be surgically implanted with the patient under general anesthesia. The INS **210** may be implanted in a subcutaneous pocket inferior to the clavicle over the pectoralis fascia. The distal end of the STL **230** (cuff **235**) may be implanted on the hypoglossal nerve or a branch of the hypoglossal nerve in the submandibular region, and the proximal end of the STL **230** may be tunneled under the skin to the INS **210**. The RSL **220** may be tunneled under the skin from the INS **210** to the rib cage and placed on both lateral sides of the costal margin. The INS **210** detects respiration via the RSL **220** using bio-impedance and stimulates the hypoglossal nerve via the STL **230** synchronous with inspiration.

[0020] Further aspects of the HGNS system **100** may be found in U.S. Provisional Patent Application No. 61/437, 573, filed Jan. 28, 2011, entitled OBSTRUCTIVE SLEEP APNEA TREATMENT DEVICES, SYSTEMS AND METHODS, the entire disclosure of which is incorporated herein by reference.

[0021] Patients with obstructive sleep apnea have repeated episodes of complete (apnea) or partial (hypopnea) upper airway collapse during sleep. The upper airway is generally defined by four walls: the posterior pharyngeal wall, the right and left lateral pharyngeal walls, and anteriorly, the soft palate and the tongue. The posterior pharyngeal wall is relatively fixed to the spinal column. Thus, collapse of the upper airway generally involves, depending on the level and mode of collapse, the tongue, the soft palate and/or the lateral walls. In rare cases, collapse may involve the nasopharynx and/or hypopharynx. As seen in FIG. 2A, the tongue

and the soft palate have been displaced posteriorly, thus occluding the airway at the level of the tongue (retro-glossal collapse) and at the level of the soft palate (retro-palatal collapse). As seen in FIG. 2B, activation of the genioglossus muscle, for example by HGNS, causes anterior displacement of the tongue, thus opening the retro-glossal airway space. Activation of the genioglossus muscle can also cause anterior displacement of the soft palate, thus opening the retro-palatal airway space. Although not visible in this view, activation of the genioglossus muscle can further cause lateral displacement of the lateral pharyngeal walls, thus further opening the upper airway. In this manner, activation of the genioglossus muscle, for example by HGNS, can mitigate upper airway collapse in OSA subjects.

[0022] Although the effect of genioglossus activation on the tongue to open the retro-glossal airway is predictable given the mechanism of action, the effect of genioglossus activation on the soft palate and lateral walls has been heretofore poorly understood and variable across subjects. Nevertheless, in the majority of OSA patients, the soft palate and the lateral walls can contribute to upper airway collapse, alone or in combination with the tongue. Thus, observing these effects can be important to predicting the success of HGNS therapy. This is particularly true if the soft palate and/or lateral walls are known to contribute to airway collapse for a given OSA patient.

[0023] The present invention offers a method to mimic genioglossus activation to observe and assess the effects thereof on structures of the upper airway. The method generally involves causing the tongue to protrude while observing the response of the upper airway using an imaging technique. In general, the desired response is an increase in airway size. An adequate increase in airway size during the tongue protrusion maneuver is indicative of likely therapeutic success with HGNS. If an adequate increase in airway size is observed during the maneuver, a HGNS device may be implanted in the patient with a higher confidence of a successful outcome.

[0024] With reference to FIG. 3A, a naso-endoscope **400** may be used to visually observe the upper airway while the patient is awake in the supine position. Alternatively, the observation may be made while the patient is in a seated or semi-recumbent position. A conventional naso-endoscope **400** including a fiber optic shaft **410** and a hand piece **420** may be used. Hand piece **420** may include a light source and a viewing window, and/or facilitate connection to ancillary imaging equipment (e.g., light source, camera, monitor, recorder, etc.). The patient may be asked to volitionally protrude his/her tongue straight and to its maximal extent with the mouth open and the lips loosely touching the tongue. Alternatively, the tongue protrusion may be performed sub-maximally, which may limit muscle contraction to the genioglossus without recruiting other musculature. Also alternatively, the tongue protrusion may be performed by asking the patient to point the tip of the tongue to one side or the other, which may more closely mimic unilateral hypoglossal nerve stimulation. The distal end of the endoscope may be positioned superior to the soft palate and substantially parallel with the posterior pharyngeal wall to visualize the retro-palatal space. The distal end of the endoscope may be positioned inferior to the soft palate, superior to the tongue base and substantially parallel with the posterior pharyngeal wall to visualize the retro-glossal space. An example of the view of the retro-palatal upper

airway space with the tongue in a relaxed (nominal) position is shown in FIG. 3B, and the same view with the tongue protruded is shown in FIG. 3C. As can be seen by comparing the views in FIGS. 3B and 3C, tongue protrusion can result in an increase in airway size, including area, circumference, anterior-posterior dimension, and lateral dimension. The increase in airway size at the level of the tongue and palate may be most discernable by an increase in anterior-posterior (AP) dimension between the posterior pharyngeal wall and the posterior side of the tongue base (retro-glossal) and soft palate (retro-palatal), respectively. Since the posterior pharyngeal wall is fixed relative to the spinal column, the increase in AP dimension involves anterior displacement of the tongue and soft palate, respectively. The increase in airway size may also be discernable by an increase in lateral dimension between the right and left lateral pharyngeal walls.

[0025] During the tongue protrusion maneuver, observing an adequate increase in size of the retro-glossal airway is predictive of HGNS efficacy in patients with isolated tongue base collapse. However, as mentioned above, the soft palate contributes to upper airway collapse in the majority of OSA patients, thus also observing an increase in size of the retro-palatal airway during the tongue protrusion maneuver is predictive of HGNS efficacy in patients with isolated soft palate collapse and combined tongue plus soft palate collapse.

[0026] By way of example, not limitation, the following procedure may be followed to conduct the assessment and tongue protrusion maneuver. With the patient awake in the supine position, a nasal endoscope is inserted into the pharynx via one of the nares to allow visualization of the upper airway. Video and still images may be captured at both the retro-palatal and retro-glossal levels to document the effect of different maneuvers on anatomic structures of the upper airway (tongue, palate, epiglottis, pharyngeal walls, etc.). When imaging the retro-palatal level, the endoscope may be placed such that all four walls (soft palate, posterior wall, and the two lateral walls) of the pharynx are visible before, during and after maneuvers. Similarly, when imaging the retro-glossal level, the endoscope may be placed such that all four walls (tongue base, posterior wall, and the two lateral walls) of the pharynx are visible before, during and after maneuvers. The endoscope may be placed such that it runs generally parallel to the posterior wall and provides a symmetric field of view. This may be achieved by initially placing the distal end of the endoscope near the level of the epiglottis and subsequently pulling back to the desired level. The patient then performs a series of maneuvers, including a tongue protrusion maneuver while breathing through their nose. The tongue protrusion maneuvers involves voluntary maximal straight tongue protrusion with lips loosely touching the tongue, with the mouth completely open, and/or with the teeth clenched closed. Other maneuvers such as a Mueller maneuver (inspiratory efforts against a closed airway) may be performed as well. Each maneuver is held for 2:2 seconds, and performed several times while data (images and measurements) are gathered.

[0027] Alternative non-volitional tongue protrusion maneuvers include, for example, manually gripping and pulling the tongue anteriorly (e.g., by the physician), using a tongue retaining device (e.g., as used for the treatment of OSA), both of which are non-invasive. Another alternative is to stretch the palatoglossal arch by pushing the tongue

down (depress tongue), by pushing the arch laterally outward, or by pulling the arch anteriorly (all palatoglossal maneuvers) using a tongue depressor or similar device. The palatoglossal maneuver may be used in place of or in combination with the tongue protrusion maneuver, and the entire description herein with respect to the tongue protrusion maneuver is applicable to the palatoglossal maneuver. Other alternative non-volitional tongue protrusion maneuvers include, for example, sub-mental stimulation and intramuscular stimulation (using fine wire electrodes, for example), both of which are relatively more invasive, but have the benefit of more selectively activating the genioglossus muscle alone to more closely mimic HGNS, as compared to volitional tongue protrusion which may recruit more than the genioglossus muscle.

[0028] Although naso-endoscopy is perhaps the most practical imaging technique to employ to assess the response of the upper airway to the tongue protrusion maneuver, other imaging techniques may be used as well. For example, x-ray imaging, fluoroscopy, x-ray computed tomography (CT), and optical coherence tomography (OCT) are suitable alternatives. These alternatives may provide more quantitative measurements by using a reference marker of known dimension in the field of view. Alternatively, improvements may be made to conventional naso-endoscopes to facilitate more quantitative measurements. For example, with reference to FIG. 3D, conventional naso-endoscope 400 includes a fiber optic shaft 410 and a hand piece 420. The distal end of the shaft 410 may include an attached extension 430 having a tip 440. The extension 430 positions the tip 440 into the field of view and may be approximated to the upper airway structure being visualized. The tip 440 may have a known dimension (e.g., diameter of 1 French or 3 mm), such that quantitative measurements of upper airway structures may be made by comparison. Other devices to make quantitative measurements may be employed, such as a laser pointer of known beam diameter projected onto the upper airway structure of interest. As an alternative, a catheter (e.g., nasogastric, nasoesophageal or nasopharyngeal catheter) may be inserted into the nasopharynx such that it resides in the field of view of the endoscope to serve as a quantitative reference of known dimension (e.g., diameter).

[0029] As mentioned above, the upper airway assessment during tongue protrusion maneuver may be used as a screening tool wherein the patient is treated with the desired therapy (e.g., HGNS) only if the increase in size of the upper airway meets a predefined criterion. To this end, the response of the upper airway may be measured using a qualitative scale such as a visual analog scale of 0-10, wherein 0 represents a closed airway and 10 represents a completely open or patent airway. The airway size may be scored with the tongue at rest and during the tongue protrusion maneuver. The patient may be treated if the difference between the two scores meets a threshold, if the score during the maneuver meets a threshold, or if both the difference between the scores and the score during the maneuver meet thresholds (e.g., 5 on a scale of 0-10).

[0030] Alternatively, the response of the upper airway may be measured using a quantitative scale such as: a pixel count of captured images which may be representative of cross-sectional area; a linear dimension such as anterior-posterior and/or lateral; or a measure of circumference. Here again, the airway size may be measured (e.g., pixel count, AP length, and/or lateral width) with the tongue at rest and

during the tongue protrusion maneuver. The patient may be treated if the difference between the two measures meets a threshold, if the measure during the maneuver meets a threshold, or if both the difference in measures and the measure during the maneuver meet thresholds.

[0031] In each case, the threshold may be a percentage increase in size (e.g., difference in AP length=50%), an absolute value (e.g., difference of AP length=0.5 cm), or a relative value. The relative value may be with reference to an anatomical landmark such as the width of the superior aspect of the epiglottis (e.g., difference in AP length=50% of epiglottal width).

[0032] Other response criteria observed during the tongue protrusion maneuver, in addition to an increase in airway size, may be used as well. For example, movement of the hyoid bone may be observed visually, by palpation or by x-ray. Movement of the hyoid bone in an anterior direction and/or inferior direction during the tongue protrusion maneuver may be predictive of therapeutic success with HGNS.

[0033] As mentioned above, although the effect of HGNS and genioglossus activation on the tongue to open the retro-glossal airway is predictable given the mechanism of action, the effect of genioglossus activation on the soft palate and lateral walls has been heretofore poorly understood. The explanation lies in the mechanical linkages between the genioglossus and other pharyngeal structures defining the upper airway. The linkages are primarily muscular, and can be effective without independent activation. Nevertheless, it may be desirable to independently activate any one or a combination of the muscular structures described below by stimulating the muscle directly or by stimulating the corresponding motor nerve innervating the muscle.

[0034] With reference to FIG. 4, the mechanical linkages may be explained in more detail. By way of context, the hypoglossal nerve (cranial nerve XII) innervates the genioglossus muscle, which is the largest upper airway dilator muscle. Activation of the genioglossus muscle causes tongue protrusion and, in some cases, anterior displacement of the soft palate, due to linkage via the palatoglossal arch (muscle). Anterior displacement of the soft palate, in turn, can cause tension to be applied to the lateral pharyngeal walls via the palatopharyngeal arch (muscle), the effect of which is discussed in more detail below. Thus, activation of the genioglossus muscle causes opening of the upper airway at the level of the tongue base (retro-glossal space) and, in some cases, at the level of the soft palate (retro-palatal space). Because the linkage between the genioglossus and the soft palate via the palatoglossal arch varies across subjects, the response to HGNS at the level of the palate will vary as well. This is significant because most people with OSA have some involvement of the palate during obstructive events, and it may be helpful to identify those subjects with inadequate retro-palatal opening due to poor linkage (i.e., poor coupling) between the genioglossus and soft palate, possibly due to tissue redundancy (i.e., slack) in the palatoglossus. Tissue redundancy may also be present in the lateral pharyngeal walls due to the presence of adipose tissue (i.e., fat) at discrete locations (e.g., fat pads) or distributed throughout the pharyngeal walls, particularly in patients with high BMI.

[0035] The anatomical linkage between the tongue base (genioglossus) and the soft palate via the palatoglossal arch may be more clearly seen in FIGS. 5 and 6. The palatoglos-

sus muscle forms the palatoglossal arch and the anterior-inferior aspect of the soft palate on either side of the uvula. The inferior and lateral ends of the palatoglossus muscle insert into the genioglossus muscle. Posterior to the palatoglossal arch are the palatine tonsils, and posterior to the palatine tonsils is the palatopharyngeus muscle forming the palatopharyngeal arch and the posterior-inferior aspect of the soft palate on either side of the uvula. The inferior and lateral ends of the palatopharyngeus muscle insert into the lateral walls of the pharynx. The soft palate is also linked to the lateral pharyngeal walls inferiorly via the pharyngoepiglottic fold as best seen in FIG. 7. Activation of the genioglossus serves to pull the soft palate anteriorly via the palatoglossal linkage. Anterior displacement of the soft palate serves to apply anterior and lateral (outward) tension to the lateral pharyngeal walls via the palatopharyngeal linkage as well as the inferior lateral pharyngeal walls via the pharyngoepiglottic linkage.

[0036] The anatomical linkage between the tongue base (genioglossus) and the lateral pharyngeal walls may be better appreciated with reference to FIG. 8. The anterior-inferior aspect (not visible) of the styloglossus muscles insert into the genioglossus, and the posterior-superior aspect of the styloglossus muscles attach to the styloid process. Similarly, the anterior-inferior aspect (not visible) of the stylopharyngeus muscles insert into the lateral pharyngeal walls, and the posterior-superior aspect of the stylopharyngeus muscles attach to the styloid process. The glossopharyngeal aspects of the superior pharyngeal constrictor muscle also insert into the genioglossus. Thus, activation of the genioglossus serves to apply tension to the styloglossus and the glossopharyngeal aspects of the superior pharyngeal constrictor muscle, which in turn apply lateral outward tension to the lateral pharyngeal walls by virtue of the lateral outward position of the styloid process and the linkage via the stylopharyngeus muscles.

[0037] In sum, activation of the genioglossus muscle opens the retro-glossal airway as well as the retro-palatal airway via the linkages described above. In addition, activation of the genioglossus muscle serves to open the lateral pharyngeal walls via the linkages described above. However, the linked effects on the soft palate and the lateral pharyngeal walls is not present in all subjects but may be important for therapeutic success of HGNS depending on the level and mode of collapse in a given patient. By using a tongue protrusion maneuver to mimic the effect on the genioglossus muscle seen with HGNS, the response of the soft palate and lateral walls may be observed using endoscopy, for example. If the palatal and lateral walls respond sufficiently to the tongue protrusion maneuver, the likelihood of successful treatment with HGNS increases. Thus, observing the response of upper airway structures to the tongue protrusion maneuver may be used as a screening tool prior to implantation of a HGNS device.

[0038] Optionally, it may be desirable to observe the response of the airway at the level of collapse. The level of collapse may be determined during sleep or simulated sleep (e.g. sedation) using known techniques such as drug induced sleep endoscopy (DISE), or may be determined by examination of the airway structures using known techniques such as naso-endoscopy. The airway may collapse at the level of the tongue base (i.e., retro-glossal), at the level of the palate (i.e. retro-palatal), or both levels. Because most OSA patients have palatal involvement in airway collapse, it may

not be necessary to determine the level of collapse. In this case, collapse may be assumed to occur at least at the level of the palate, and therefore an adequate response (e.g., increase in airway size) in the retro-palatal space during the tongue protrusion maneuver would be indicative of likely therapeutic success with HGNS.

[0039] The principles of the present invention may be applied to other therapeutic interventions for OSA involving the upper airway. For example, the tongue protrusion maneuver may be used as a screening tool for surgery of the upper airway, such as uvulopalatopharyngoplasty (UPPP), palatal implants, genioglossus advancement, maxilla-mandibular advancement, etc. Also, the tongue protrusion maneuver may be used as a screening tool for oral appliances such as mandibular repositioning devices, tongue retaining devices, etc.

[0040] Those skilled in the art will recognize that the present invention may be manifested in a variety of forms other than the specific embodiments described and contemplated herein. Accordingly, departures in form and detail may be made without departing from the scope and spirit of the present invention as described in the appended claims.

1-20. (canceled)

21. A method of assessing a patient's suitability for an upper airway stimulation therapy, the method comprising:

inserting a visualization device into the patient's upper airway to evaluate tissue redundancy in pharyngeal walls due to a quantity of adipose tissue;

documenting a degree of tissue redundancy; and

receiving a criterion relating to the tissue redundancy, the criterion concerning the patient's suitability for the upper airway stimulation therapy.

22. The method of claim **21**, wherein the degree of tissue redundancy due to the quantity of adipose tissue is observed in the patient's soft palate and/or lateral pharyngeal walls.

23. The method of claim **21**, further comprising:

documenting the patient's body mass index (BMI).

24. The method of claim **23**, wherein the degree of tissue redundancy corresponds to a magnitude of the patient's BMI.

25. The method of claim **21**, further comprising:

protruding the patient's tongue without nerve stimulation while observing a response of the patient's airway with the visualization device.

26. The method of claim **21**, wherein the documenting of the degree of tissue redundancy takes place when the patient is subjected to drug-induced sleep endoscopy (DISE).

27. The method of claim **21**, further comprising:

evaluating a degree of upper airway collapse, wherein the upper airway comprises a posterior pharyngeal wall, a right lateral pharyngeal wall, a left lateral pharyngeal wall, a soft palate and a tongue.

28. A method of assessing a patient's suitability for an upper airway stimulation therapy, the method comprising:

inserting a visualization device into the patient's upper airway to evaluate tissue redundancy in pharyngeal walls due to a quantity of adipose tissue;

documenting a tissue redundancy presence due to a quantity of adipose tissue; and

receiving a criterion relating to the tissue redundancy, the criterion concerning the patient's suitability for the upper airway stimulation therapy.

29. The method of claim **28**, wherein the tissue redundancy presence due to the quantity of adipose tissue is observed in the patient's soft palate and/or lateral pharyngeal walls.

30. The method of claim **28**, further comprising:

documenting the patient's body mass index (BMI).

31. The method of claim **30**, wherein the tissue redundancy presence corresponds to a magnitude of the patient's BMI.

32. The method of claim **28**, further comprising:

protruding the patient's tongue without nerve stimulation while observing a response of the patient's airway with the visualization device.

33. The method of claim **28**, wherein the documenting of the tissue redundancy presence takes place when the patient is subjected to drug-induced sleep endoscopy (DISE).

34. A method of assessing a patient's suitability for an upper airway stimulation therapy, the method comprising:

recording with an imaging device at least a portion of tissue redundancy in pharyngeal walls due to a quantity of adipose tissue;

recording a tissue redundancy; and

generating a record of said recordings, wherein the record includes a characterization of said tissue redundancy, wherein the record is configured for comparison to a criterion relating to the tissue redundancy, the criterion concerning the patient's suitability for the upper airway stimulation therapy.

35. The method of claim **34**, wherein the characterization of said tissue redundancy due to the quantity of adipose tissue is observed in the patient's soft palate and/or lateral pharyngeal walls.

36. The method of claim **34**, further comprising:

documenting the patient's body mass index (BMI).

37. The method of claim **36**, wherein the characterization of said tissue redundancy corresponds to a magnitude of the patient's BMI.

38. The method of claim **34**, further comprising:

protruding the patient's tongue without nerve stimulation while observing a response of the patient's airway with the imaging device.

39. The method of claim **34**, wherein the record is generated when the patient is subjected to drug-induced sleep endoscopy (DISE).

40. The method of claim **34**, further comprising:

evaluating a degree of upper airway collapse, wherein the upper airway comprises a posterior pharyngeal wall, a right lateral pharyngeal wall, a left lateral pharyngeal wall, a soft palate and a tongue.

* * * * *